



ROYAL COLLEGE OF  
PHYSICIANS AND  
SURGEONS OF GLASGOW

---

***Frcs knights*** 

***FRCS Glasgow***  
***Experience***  
***5 trials to success***

***by***  
***Kareem Elsheikh***

I start with the name of Allah Al-Rahman Al-Rahim.

1st I want to thank Allah Al-Ali Al-Kadeer for my success. Then I will mention some advices before starting.

- **Y**ou must know that success is a gift from the God just you try hard, study & study, practice & practice if you succeed so you are winner & if failed do not be sad it is not a defect in you it is only The God's will . Stand up try again & again
  
- **S**ources for study are different so find books that you feel comfort with it. For me:
  - **Wong** : was my 1ry source I studied it more than 15 times in my 5 trials I think it is the corner stone in 3rd part although it has some mistakes & defects that I corrected from other sources.
  - **Dr Walled Bader Internal medicine notes**: they are very helpful in viva
  - **Wills eye manual**: It was my source in 2nd Part & was a reference in 3rd part specially in some topics that is not fulfilled in wong e.g: conjunctiva, Lid & orbit
  - **Cake Walk** : also a great book but very defective you can not study it alone. I read it fast reading then I marked on the topics that is not in wong for being repeated & studied good ( specially 1st 70 pages that are very helpful) also I copied single information by hand write to my 1ry source (wong).
  - **Kanski synopsis**: A great friend -who studded this book in his FRCs & succeeded told me to try it. I read it super fast once & I marked on the topics that is not in wong also I copied single information by hand write to my 1ry source (wong).
  - **Chua Examination techniques & cases for final FRCS**: you can find this book on chua site & The clinical multi-station examination section in chua site
  - **Past candidates experience**: very important, teaches you how to deal with the exam & what the examiners want from you also many cases can be repeated in both viva & clinical exams if you study experiences well so most of the exam will be familial to you.
  
- **P**practice & practice this is very important. Do all examinations in your clinic as you learnt from FRCs to be familial with these examination during clinical exam & to not forget any of them. These examination must be your ordinary work in your own clinic. In all exams I underwent, the candidates met in the hotel to learn the examination techniques & perform them on each other. I think this is bad as you will forget, be slow or will be unconfident in the exam. On other hand if you don't master these techniques & make them your ordinary work in the clinic so what is the benefit from FRCs for you & for your patients.
  
- **I** underwent this exam 5 times 2 in Glasgow 2 in Hyderabad & 1 in Delhi & I think all centers are the same, same examination & same examiners. only minor negative & positive points that are different between those places
  
- **P**hotos I used in this experience are so close to that was in the examination

# 1st trial Glasgow 2015

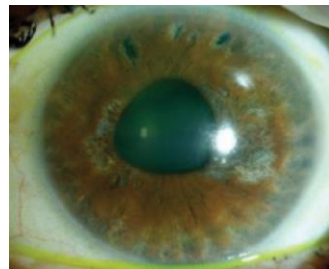
In Glasgow the good issues that clinical cases are repeated so if you read Glasgow experience well you may face many repeated cases  
Bad issue is that slit lamps are old fashion that you may take time to adjust them

## Viva exam

Was in old order (Clinical - Surgery - Internal med. & neuro.)

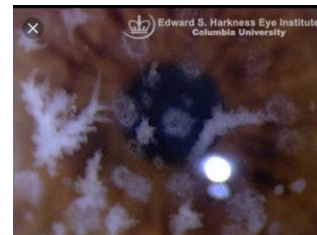### Clinical ophthalmology

- Photo of previous attack of angle closure glaucoma  
(Iris atrophy, irregular atrophic pupil, Kps & glaukomflecken)



- Visual Field shows arcuate scotoma, asked what do you think --> glaucoma,  
What if this is not progressing --> (he wanted optic disc drusen)

- Photo  
of avellino dystrophy.

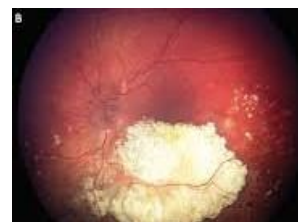

- Question: Blinding complication of Anterior Uvieties? cataract, glaucoma, Cystoid macular edema, Band keratopathy, physis pulbi (very common Question & repeated many times)

### Surgery & pathology:

- Question: on local anesthesia (peri, retrobulbar & topical) methods ,  
complication & what you prefer.

-Photo of calcified retinal mass :  
this is 2 years boy what do U think --> retinal mass  
(cottage cheese appearance) Retinoblastoma. What  
happened to this tumor ? calcification  
this girl came when she is 13 years with Rt. temple pain  
what do U think ? 2ry tumor ( osteosarcoma)- What is your  
management to this retinoblastoma



**- Question:** Essential Esotropia 30 diopters What you do --> bilateral medial rectus recession How much ---> 4mm each side what if you want to work in one eye --> MR recession + LR resection. How much ---> 5mm MR recession + 5mm LR resection. Another candidate answered why I calculate there is ready made squint tables & examiner was happy with his answer. I think it is better to give exact numbers but if you can not just mention there is ready tables.

**- Question:** DCR - ring bill - just say what is the most important complication ?  
bleeding

## Medicine & neuro

Not remembered

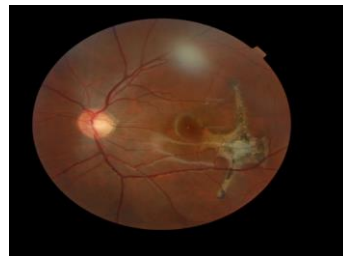- Headache all causes
- Atrial fibrillation
- young girl complains visual loss examination is good --> I told all DD of visual loss with normal appearing fundus in children he says no I said may be malingering child functional visual loss. How you examin --> tests ( mirror test , fogging , VEP ... etc)

## Clinical Exam:

### Posterior segment:

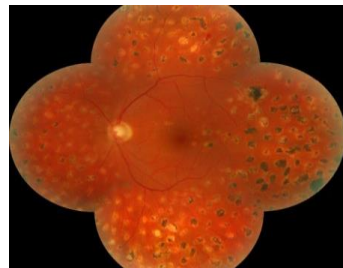
#### - 1st case:

Choroidal rupture with CNV



#### 2nd case

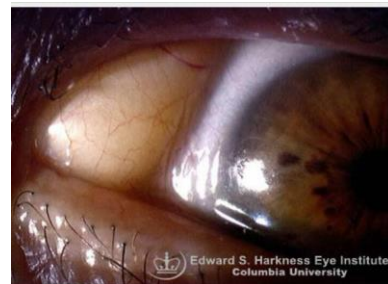look at fundus, bilateral PRP marks. What do you think? PRP for PDR. Is it successful & why ? yes as new vesseles regressed, attenuated vesseles & pale disc



### Oculoplasty :

#### - 1st case:

An old pt. Examiner elevated her both lids, there was bilateral yellow masses from upper temporal fornix. asked describe? bilateral yellow masses, soft consistency. asked what do you think? Dermolipoma, fat prolapse & DD of lacrimal gland tumors, what will you do? if Pt has no complain just follow up.



Oculoplastics-Dermolipoma

Edward S. Harkness Eye Institute  
Columbia University

- **2nd case:** An old female with ptosis. asked about tests for ptosis (levator function, lid crease & MRD ... etc) asked about DD for ptosis (neurogenic, aponeurotic, mechanical & myogenic) with application on the Pt. do mythenia tests.

- **3rd case:**

look at the pt what do you see? only Jones Pyrex tube. what is this operation? conjunctivo dacrocystorhinostomy.

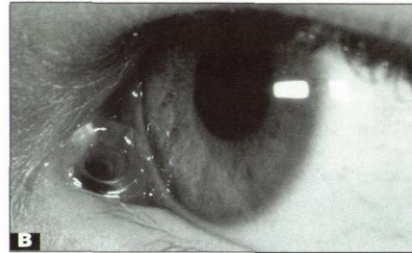
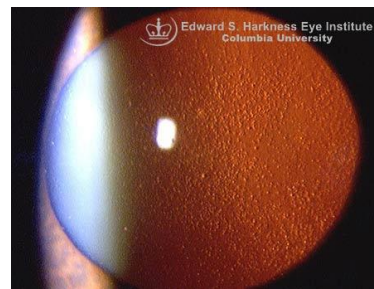
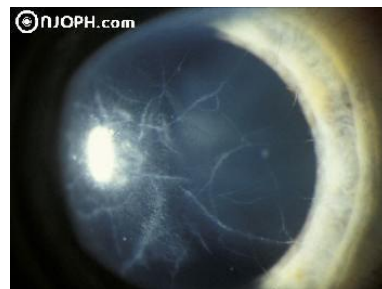

Figure 2. (B) Jones tube position in patient 1 on left side.

## Anterior segment:

- **1st case:**

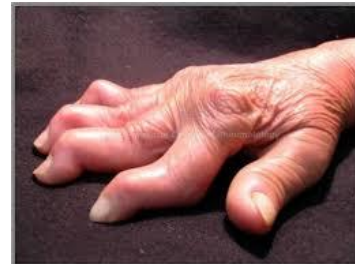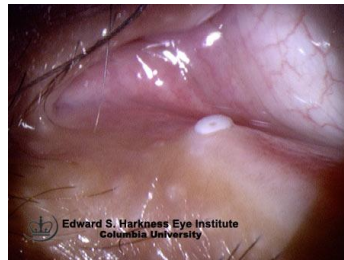Look at the cornea?



corneal lesion branching lines like lattice degeneration. Look at other eye? Cornea guttata + stromal edema (fuchs corneal dystrophy).  
**that is a strange & famous case in Glasgow that is repeated for many years.**

- **2nd case:**

Female pt, Look at anterior segment what do you see?



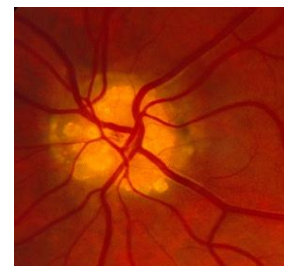there was only punctal plug. what do U think the cause ? dry eye due to rheumatoid arthritis as Pt has bilateral hand deformities. what is called? boutonier & swan neck deformity. asked about types of artificial tears.

## Neuro & ocular motility:

I failed this session

- **1st case:**

Examiner gave me direct ophthalmoscope & asked to see fundus, I was shot panicking as I did not use it before. I asked can I use slit lamp or indirect ophthalmoscope, answered NO. I failed - **This case was optic disc drusen,**

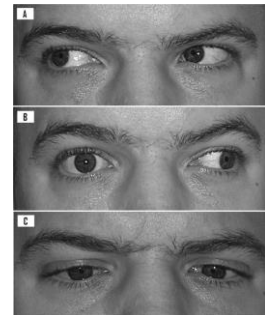


- **2nd case** Examiner gave me a glasses asked what is this. it was a glasses with ordinary prisms (not fresnal prism) one side base up & the other base down. then asked look @ the pt what is your diagnosis according this glasses. pt has hypertropia in Lt eye, Asked to do cover uncover then asked what is your diagnosis- **I failed again because I was disturbed & frustrated from the 1st case But this case was 4th nerve palsy.**

**- 3rd case:**

young male

was INO. asked What is INO, what is MLF, What is the cause. in this age multiple sclerosis, what is the ocular manifestations.?



\*\*\*\*\*

## 2nd trial Delhi 2016

Delhi is very crowded city I did not fell comfort there. Take canned food because The food is so spicy & difficult to eat. The hotel I booked (Jivitesh hotel) was good & near from clinical exam that you can go on foot in less than 4 minutes.

I remember some question from this exam

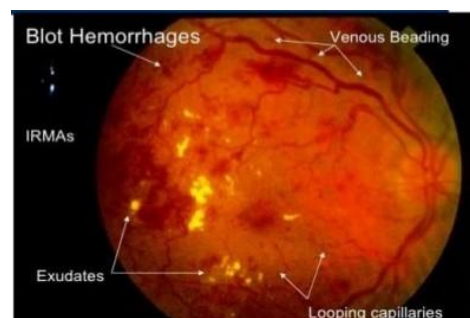
### Viva exam

Was in old order (Clinical - Surgery - Internal med. & neuro.),

### Clinical ophthalmology

**- Photo :**

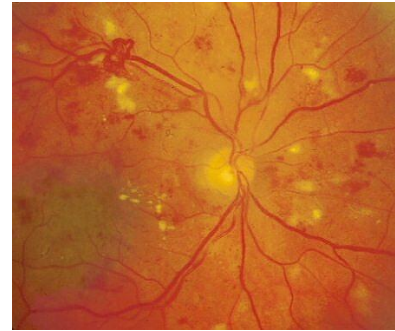sever PPDR. Asked what to do? If young age type 1 DM incompliant Pt or history of PDR in other eye I will do PRP. Asked if the Pt is compliant? I said close follow up. Asked what is CSME?





**- Photo** of PDR.

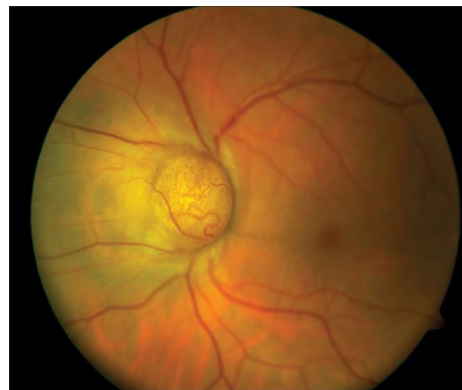Asked what you do? It is high risk PDR & needs PRP  
what is High risk PDR? what if not high risk? I consider  
any neovascularization is medical emergency & needs  
PRP. How do you do PRP & what is the laser  
parameters?



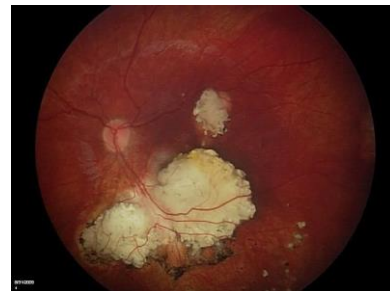## **Surgery & pathology:**

**- Question:** Naso lacrimal duct obstruction how to diagnose? Fluorescein retention, regurgitate test, Lacrimal irrigation -> hard stop, soft stop ..etc, Jones dye test step I & step II.

**- Photo** of retinal mass mushroom appearance  
arise from optic disc What do you think? a  
melanotic melanoma what else it can be?  
astrocytoma, osteoma. Ok it is melanoma what  
will you do? I mentioned the whole treatment of  
melanoma according to size & extension &  
lastly said for this tumor it is small &  
unfavorable site (optic disc) so close follow up  
as melanoma is slowly growing. What is your  
precaution in enucleation? I don't know but I  
answered not crushing optic nerve Examiner did  
not give any impression



**- Photo** Again & for the 2nd time photo of retinal  
mass in a child? retinoblastoma  
asked about treatment?  
when the Pt was 13 he developed scalp pain?  
osteosarcoma (2ry tumour)



## **Medicine & neuro:**

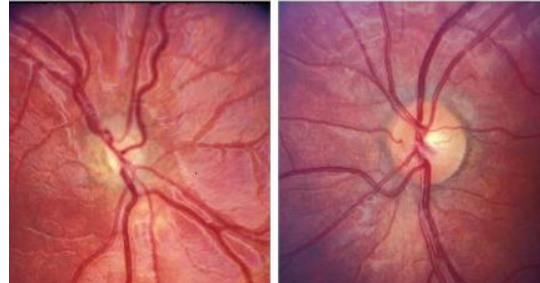
**- Question:** Pt has car accident followed by anisocoria what is your diagnosis?  
anisocoria more in light so 3rd nerve palsy, traumatic mydriasis or Adie's tonic.  
Anisocoria more in dark: Horner syndrome, pontine hemorrhage

**- Question:** Pt developed MR weakness followed by LR weakness? Myasthenia gravis,  
Thyroid eye disease, DM. What else? I don't know **he said Miller Fisher syndrome**. Discussion about Myasthenia gravis.

**- Question:** Young female with headache, Increased intracranial tension (papilledema)  
Asked about complication of Oral contraceptive pills on the brain?  
idiopathic increased intracranial tension & cavernous sinus thrombosis.

asked what else? I don not know **He said superior sagital sinus thrombosis &**  
 Asked signs & symptoms of superior sagital thrombosis? I answered  
 papilledema, headache, vomitting , tinitus & transient visual loss ( I realy did  
 not know & this was by luck & the examiner did not object to my answer).  
 asked about treatment? decrease weight, stop inciting drugs, acetazolamide  
 tab, lumbar puncture, & luboproteniel shunt.

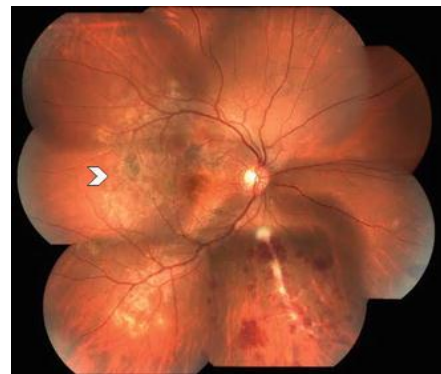
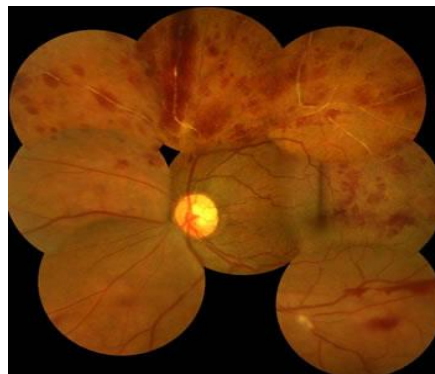**- Photo:** is divided into to halves. One  
 shows normal optic disc & the  
 other half shows optic disc  
 hypoplasia. Although it is so easy  
 but many candidates can not answer.



## **Clinical Exam:**

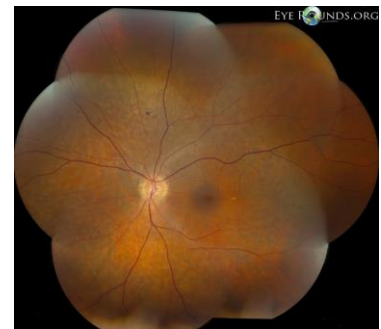### **Posterior segment:**

**- 1st case:**



Young indian male look at the fundus ? hges vascular  
 sheathing(vasculitis), vascular occlusion & peripheral retinal detachment.  
 Look at other eye? same picture. What do you think? I want to ask about  
 HIV(CMV retinitis) What else may be? syphylis. what else? DM He said No  
 return again to vasculitis. What is here is common in india can make this  
 picture? I don not know **This case was eales disease & the common in india  
 is TB.**

**- 2nd case:** pale fundus attenuated vessels & pale disc what  
 do toy think? I want to look to other eye. was same picture.  
 Examiner said look at prephery. there was some  
 pigmentation. what do you think? Retinitis pigmentosa sin  
 pigment.



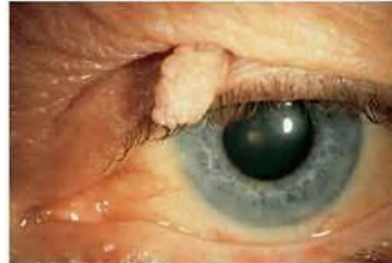### **Oculoplasty :**

**- 1st case:** was phthisis pulbi. what well you do? evisceration what if she do  
 not want? ok no problem I will leave her. **He wanted ocular prosthesis  
 (prosthetic shell) or Contact lens .**



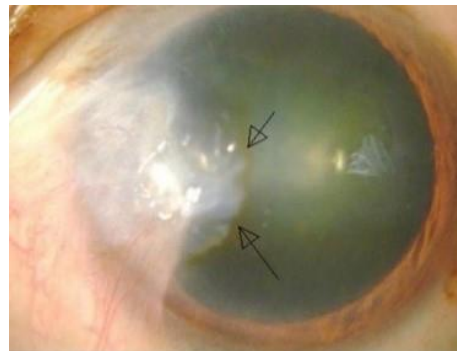
- **2nd case** was ptosis. Asked me to do ptosis measurements & I did all ptosis examinations & bells reflex. What is the cause? all DD of ptosis, What else you see in this Pt? nothing else **He wanted me to mention a skin scar of previous ptosis surgery that I did not notice. it is very important to notice scar of previous operation.**

- **3rd case:** I said papilloma he was not happy & asked me to describe what do you see. I said a lid mass pedunculated less than 1mm not attached to underlining structures, not affecting lid margin or lashes or meibomien orifices. Do you think it is malignant? no  
What will you do? excisional biopsy.



### **Anterior segment:**

- **1st case:** was middle age female. pterygium with stocker line. asked what the cause of pterygium? hyaline degeneration from sun exposure What else? don not know what if I tell you that she is a worker in a factory? he wanted micro trauma.



- **2nd case** was 10 years child with sever photophobia & can not open his eye & was very difficult to be examined, what do you see? Large corneal opacity what else? difficulty I see an AC IOL. What else? I raised his upper lid there was superior staphyloma. What is this staphyloma? thinned sclera with uveal tissue covered by conjunctiva. What the cause? Surgical induced necrotising scleritis. What is your diagnosis? complicated cataract surgery. **Notice: it is so important to elevate upper eye lid.**

### **Neuro & ocular motility:**

Again & for the 2nd time I failed the neuro session.

- **1st case:** Look at this child examine the pupil? Direct & indirect & consensual pupil reflexes. RAPD. What do you think? in this age I want to ask about trauma Traumatic optic neuropathy.

- **2nd Pt.** was young male Asked examine pupil? RAPD what will you do next? Fundus examination for optic atrophy. What else? ocular motility for INO. What else? I do not know **Untill now I did not know why I failed & I thought he may wanted me to check visual field.**

\*\*\*\*\*

# 3rd trial Hyderabad 2017

Hyderabad is better city than delhi, I went there twice & I suggest Fortune Vallabha hotel as it is good & not expensive & there is a market in front of the hotel called foodbazar that you can get your needs.

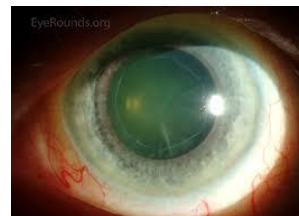
The advantages of Hyderabad center is the clinical exam which is in LV Parassade eye hospital which has good & new slit lamps & good instruments.

## Viva exam

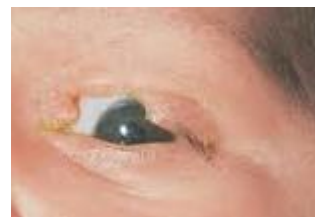Exam order is changed to Anterior segment with oculoplasty, Posterior segment & neurology & medical emergency.

### Anterior segment & oculoplasty:

-Photo of pseudoexfoliation syndrome what is difficulties during cataract surgery? 3 difficulties. subluxated lens, narrow pupil & glaucoma. How to manage subluxation? if sever ICCE if mild so capsular tension ring is used.



- Photo of upper lid defect more than half of the lid. What do you think? Lid coloboma what to do ? graft - **Cutler Beard graft**.



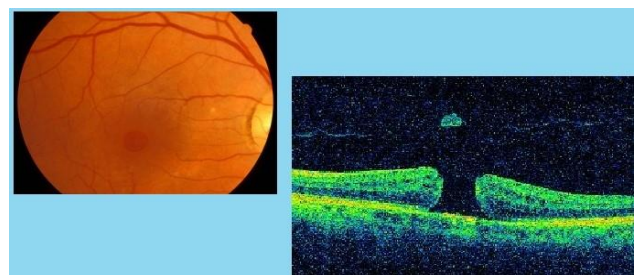
not remember other questions

### Posterior segment:

**I Failed this session**

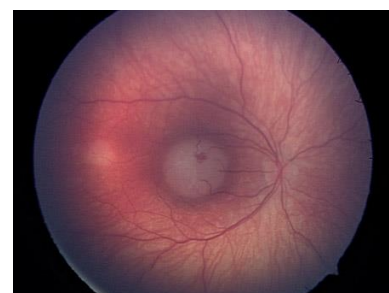- Photo:

Photo divided on 2 halves. Rt side macular hole & Lt side was OCT. what is the grading of this hole? OCT shows full thickness macular hole with PVD so it is G IV. Examiner was angry & asked what PVD? posterior vitreous detachment.



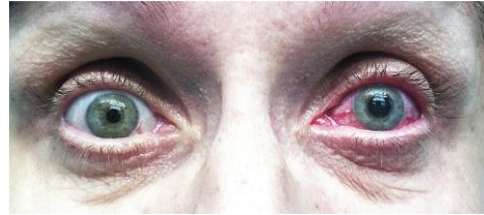He said no PVD what do you think? . **(but there was PVD )** so I said according to the hole thickness. **After the exam a college told me that the thickness was written under the photo 200u & examiner wanted GII.**

- Photo of a small mass in the macula. This is 3 years child? Retinoblastoma. how to treat? it is small so focal treatment like argon laser photocoagulation. again examiner was angry, you will hit the macula with laser. I said sorry, chemotherapy or brachy therapy.



**- Question:** You made SST to a patient & 2nd Day you find shallow AC? I said according to IOP & I gave DD shallow AC with increased IOP: malignant gl. pupillary block or suprachoroidal hge. shallow AC with decreased IOP: Wound leak, over filtration or Ciliary body detachment. Examiner was not satisfied & asked mockingly this is Your approach? I said yes. examiner was unsatisfied. **I think he wanted me to start with grades of AC shallowing** Asked how do you manage malignant glaucoma?

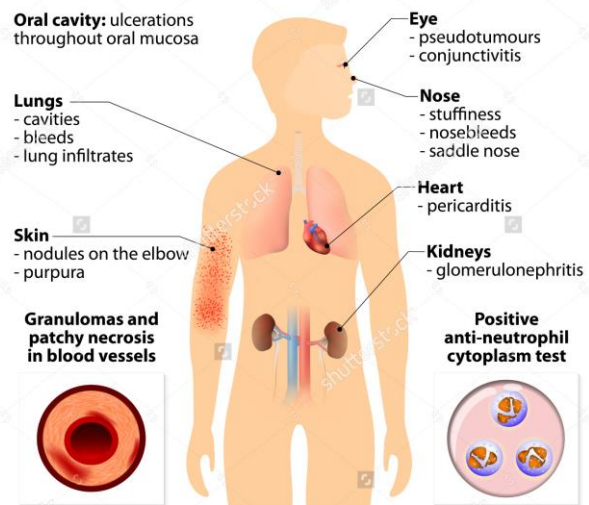
**- a Photo** of red eye (just red eye dilated pupil photo from far not showing any signs) & as I was in posterior segment session I was confused & can not realize what is the answer. Examiner said what can make red eye with dilated pupil I tried to find a posterior segment cause But I failed he said can not be Angel closure? I said yes **(but it was Posterior segment session)**. I failed this session & I felt unfair it was so close to success.



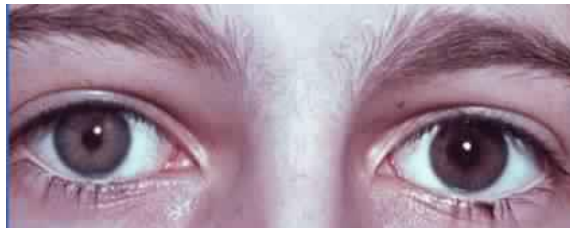## **Medicine & neuro:**

**- Question:** Pt complains Nose bleed & eye pain ? wegner granulomatosis. What do you know about W.G. systemic & ocular signs? I answered from a photo I memorize. What is the drug of choice for treatment? cyclophosphamide

## **Wegener's Granulomatosis**



**- Photo:** anisocoria with heterochromia (horner syndrome) discussion about all anisocoria DD & all chemical tests



**- Question:** Diabetic Pt in coma? asked about hypoglycemic coma management

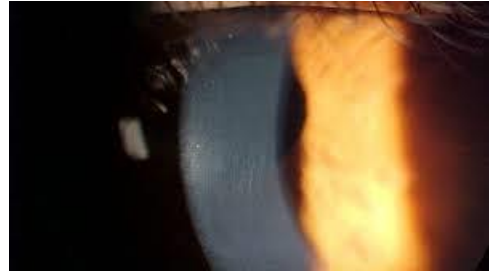
**- Photo** of optic disc hypoplasia

## Clinical Exam:

### Anterior segment:

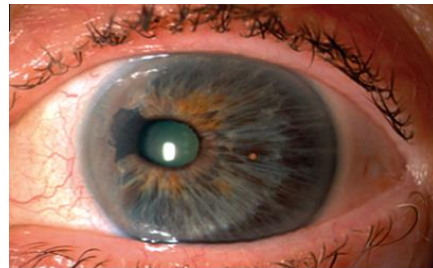
#### - 1st case :

Look at the cornea  
bilateral Vogt stria .  
bilateral keratoconus  
What will you do?  
Lamellar keratoplasty.  
Directly? No we can try  
corneal rings



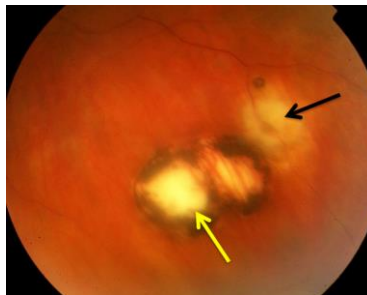
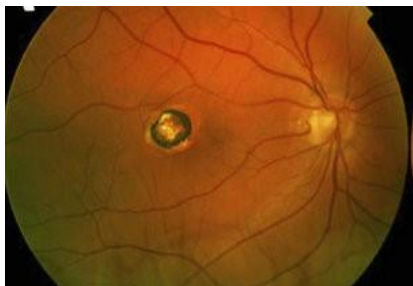
#### - 2nd case:

Examine Ant. segment?  
corectopia, ectropion uvea, iris  
atrophy & prepheral anterior  
psynechia. how do you examin iris  
atrophy? by retroillumination. Did you  
do it ? No . why? it was obvious  
What is the siagnosis? can I see other eye. it  
was normal. what do you think? irido corneal  
endothelial syndrom . what this means? I started to demonestrat the 3 types



### Posterior segment:

#### - 1st case



examine the fundus? one eye had macular scar . Look to other eye? there was  
macular scar with white lesion, PVD & vitreous haze. do you think it is active? yes  
the one with vitreous haze is active (vitritis). how do you manage? if small non  
threatning vision no treatment. examiner intrupted me do you think active macular  
toxoplasmosis not need treatment ? no it needs treatment. How? pyremethamine,  
sulfadiazine & prednisolon (triple therapy)

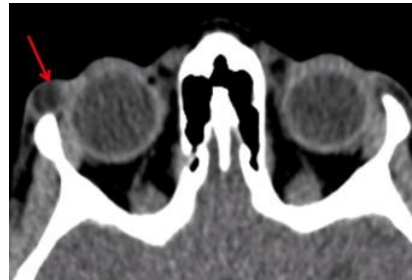
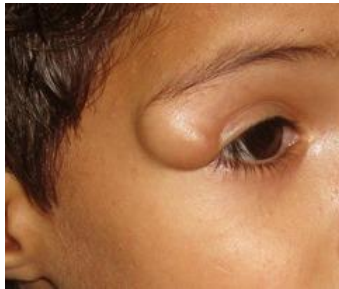#### - 2nd case:

Examine fundus with indirect ophthalmoscope? total retinal detachment. examiner  
said ok enough. I asked more time to find the break he said enough as he didnot  
want to harm the pt.



## Oculoplasty :

### - 1st case:



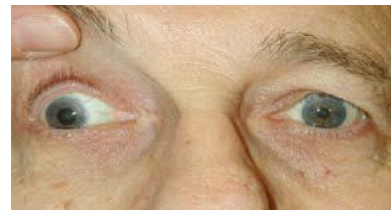Examine the Pt? Rt temporal mass not fixed to skin, mobile & well circumscribed. what do you think? Dermoid cyst. what else it can be? Lacrimal gland tumor orbital tumor (hemangioma lymphangioma) . then he open a computer photo for CT scan, what do you think? I pointed to the mass & said well circumscribed encapsulated. What is your diagnosis? dermoid cyst.

### - 2nd case:

Unilateral axial exophthalmos . I examined from behind & both sides. Examiner asked to measure exophthalmos, I used my ruler it was 25 mm, what is DD? I mentioned DD of unilateral exophthalmos ... examiner: ok it is thyroid what is your management? general examination for hand ( pulse, tremors, wormth & acropathy) pretebial mexedema & examination of thyroid goiter. Examiner asked about treatment?

## Neuro & ocular motility:

complete ptosis with exodeviation & dilated pupil ( pupillary involving 3rd nerve palsy). Examiner askedme to do pupillary tests.



### -2nd case:

Do ocular motilty to this Pt? it was a case of bilateral duan syndrom type 3 asked about types of duane syndrom ? & what is the name of this classification? I don't know the name. (answer is Huber classification)

\*\*\*\*\*



# 4th trial Glasgow 2017

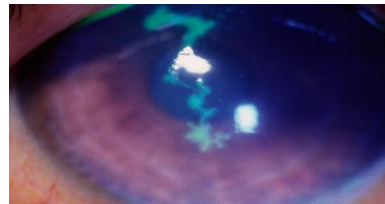
## The big fail

Every exam I failed in 1 session . In glasgow 2015 & Delhi I failed neuro & ocular motility clinical exam. In hyderabad I failed only in Posterior segment viva exam. But in glasgow 2017 I failed half of the sessions & my feedback result was embaessing. I hated that exam & want not to remember it So I forgot most of it.

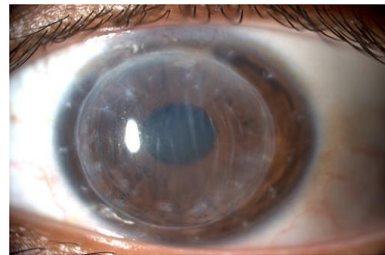
## Viva exam

### Anterior segment & oculooplasty:

-Photo of Dendritic corneal ulcer Due to Herpes simplex. Why herpes semples? terminal pulbes, large size & central



- photo of Corneal graft rejection. There is corneal edema. Examiner asked what type? stromal rejection how You treat ? here I confused & said it may be graft failure Examiner asked what is the difference? in graft failure no inflammation. How you treat? confused again & said hyper tonic saline & steroid. Ask what you will give hypertonic saline or steroids? Both. **The right answer that it was graft rejection & treatment is by pred-fort ED every one hour.**



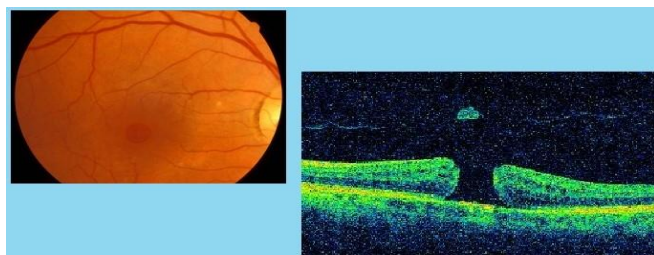
## Medicine & neuro:

- Question: About medical & ophthalmological symptoms & signs of sarcoidosis? Invistigation? & treatment?

- Question: Young femal complains increase weight despite little food intake & sleeps alot?? hypothyroidism

## Posterior segment:

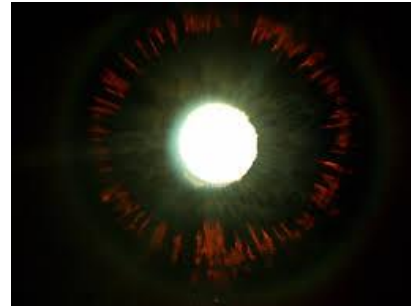
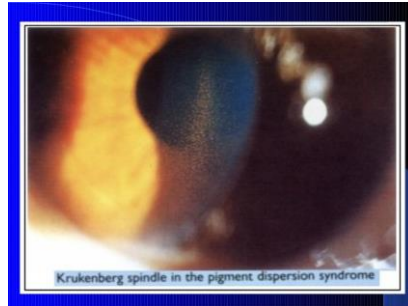-Same photo of macular hole (in hyderabad) again



- **Question:** middle age Pt with high myopia suddenly developed visual loss? CNV, Retinal detachment. Causes of CNV? what is easier to treat CNV in ARMD or high myopia? CNV in high myopia carries better prognosis.

## **Clinical Exam:** **Anterior segment:**

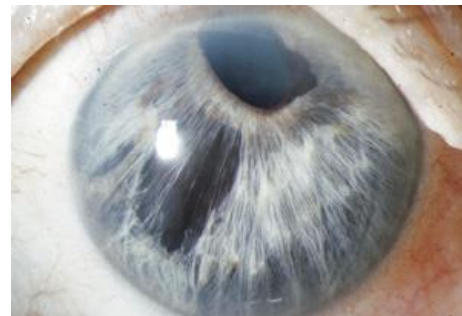
### **- 1st case**



Examine the cornea ? krukenberg spindel (pigment dispersion syndrom. What is 2nd sign you want to see? Iris transillumination defects. How? by retroillumination. then do it? slit lamp was old & different from I used to work with it take long time to be adjusted. what next? angel for hyper pigmented TM & Schwalb's line. Do you give Glaucoma TTT? No except if there is glaucoma. what is the percentage of glaucoma in PDS? 15% in 15 years (as it is written in wong but this was wrong & the right answer in kanski is Third of cases & in cake walk Third to half cases)

### **-2nd case**

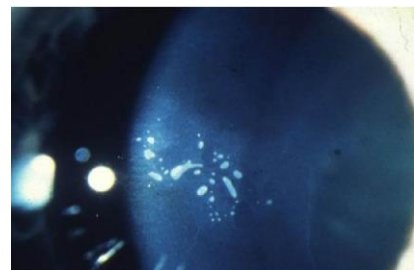- anterior psynechia posterior embryotoxon, corectopia, iris atrophy & AC IOL which was displaced to the side (not central) & corneal wound of ECCE . Asked what do you think? I want to see other eye which was the same also has displaced Ac IOL. Examiner asked about diagnosis? I want to see his teeth.



Examiner said every thing is good. I answered reger's anomaly. Asked why ECCE not phaco? didnt answer (he wanted subluxated lens). Asked why IOL is dislocated? Because it is small. Asked how would you know appropriate IOL size? didnt answer (he wanted white to white measurement) Examiner was unhappy

### **3rd case:**

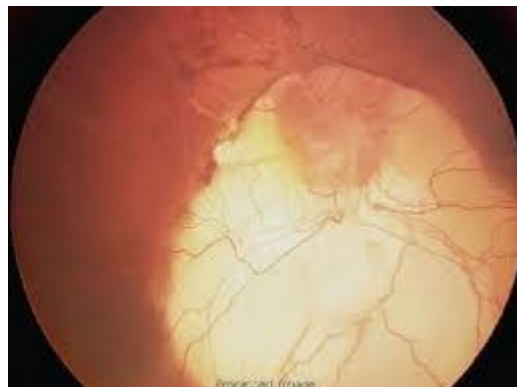examin the cornea? ther is superficial lesion like vesicles & dots. what is te level? epithelial. whats your diagnosis? Can I see other eye. it was normal. It is like corneal dystrophy but it is unilateral? Examiner asked again what type of dystrophie? map - dot -finger print



## **Posterior segment:**

### **1st case:**

examiner gave me indirect ophthalmoscope Asked to examine? pupil was not dilated well, there was iris coloma & the retina shows larg coloboma. asked what type ? larg coloboma ( right answer is complete coloboma as it extends from the iris to retina)



### **2nd case:**

Examine Anterior segment then posterior segment?

this case has many signs & the examiner want the candidate to discover all signs Anterior segment: ban keratopathy, prepheral ant psynechia, Iris atrophy & pseudophakia. Posterior segment: silicon filled eye, laser retinopexy & prepheral retinal detachment (there was more signs in this eye but I do not remember now)

## **Neuro & ocular motility:**

### **1st case:**

Look to this Pt what do you see? Lt exophthalmos. Examine pupil reflexes? Lt APD . Examine ocular motility? Frozen eye (3rd + 4th + 6th nerve palsy) what do you want to do? I want to examine corneal sensation for 5th nerve palsy & this a case of orbital apex syndrom ( 2nd, 3rd, 4th, 5th & 6th nerve palsies + proptosis)

### **2nd case:**

Examine ocular motility? I examined versions in 9 cardinal position there was Rt abduction limitation. what do you think? 6 nerve palsy. Examiner said NO examine again? again there is limitation in Lt abduction no narrowing of palpebral fissure in adduction (not duane). I cannot reach diagnosis, I failed

## **Oculoplasty :**

### **1st case:**

it was a ptosis case. how to examine? I examined levator function, Margin reflex distance & lid crease hight. what could be the cause? Neurogenic : I did ocular motilty for 3rd nerve & cogan twitch sign & fatigue test for mythenia, move your jew from side to side ( jew winking) all negative. Not apaneurotic , No masses (not mechanical) Myogenic: Shaking hands for myotonic dystrophy & ocular motility for Chronic progressive external ophthalmoplegia. Examiner was satisfied he said Ok this is CPEO what do you want to do ? Muscle biopsy: ragged red fibers.

### **2nd case:**

I'm not remembering it

\*\*\*\*\*

# 5th trial: Hyderabad 2018

## Date with success

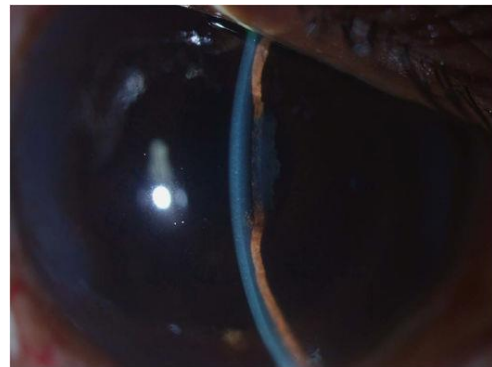
This was not the best trial to me but it was the trial that I succeeded. As I told before success is a gift from mighty god.

### Viva exam

#### Anterior segment & oculo-plasty:

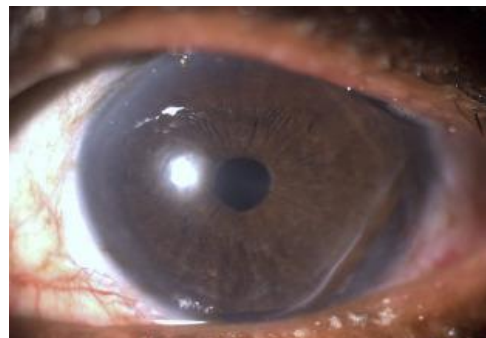**- Photo:**

1st beam shows the cornea & 2nd one shows iris so it is shallow AC with irido corneal touch G3 (pupil-corneal touch). Asked: this was after a trab. surgery what do you think? again DD of shallow AC after trab with high IOP & Low IOP ( as you see questions are repeated so experience reading is very important)



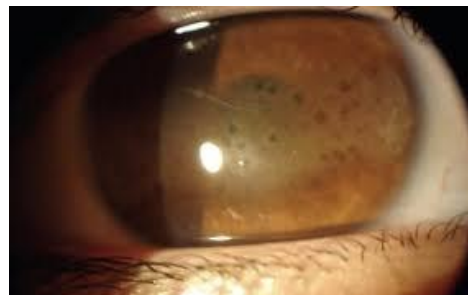**- Photo:**

peripheral ulcerative keratitis (PUK)  
Asked DD & management? (don not forget in management 1st to do is corneal scrub for C/S although PUK is mostly autoimmune)



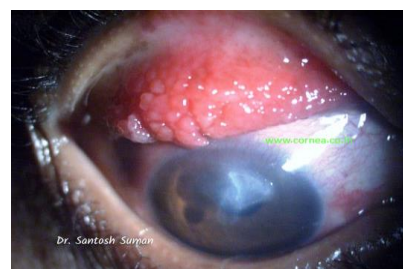**- Photo:**

central white band shows holes & separated from the limbus by clear zone. What do you think? Band keratopathy. What is the cause? chronic iridocyclitis, silicon filled eye, phthisis bulbi or systemic hypercalcemia. How do you manage? removal of big scales with forceps & chelation with EDTA. What is the concentration of EDTA you use? I do not know



**-Photo:**

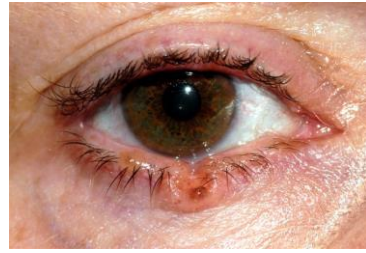Giant papillae with shield ulcer. (Vernal keratoconjunctivitis. What is treatment? scrubbing the ulcer topical lubricant, Anti histaminic & short course of topical steroid. What is the causes of Giant papillae? VKC, CL wear, Ocular prosthesis, Foreign body or protruded suture.





**- Photo:**

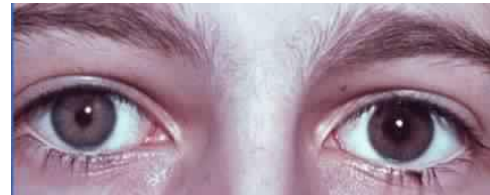Basal cell carcinoma. what is the management?  
Excisional biopsy with MOHS technique or frozen section.



**Medicine & neuro:**

**-Photo :**

(again horner syndrom that is repeated many times in this session). What do you see? Rt miosis with hypochromia horner syndrom. Examiner was upset & repeated what do you see? I said sorry it is a case of anisocoria. How do you manage?



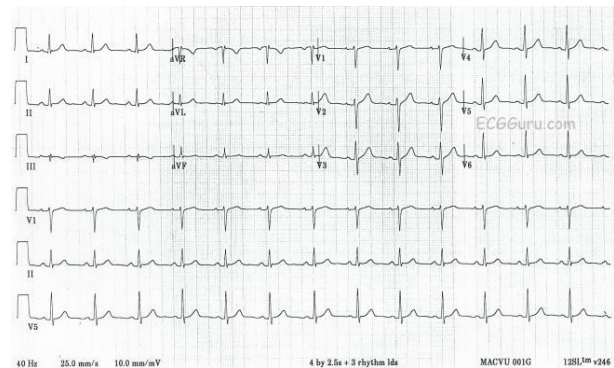
examine in the dark & in the light ( I mentioned DD of anisocoria in dark & light including all pharmacological tests & how to differentiate between all causes)

**-Question:**

7 years old girl complaining week vision in Rt eye 6/24 & 6/12 & you examine her eye & was normal what do you think? I give DD of all causes of loss of vision in childhood with normal looking eye & examiner was saying NO NO NO. I said refractive error he said NO. I stopped talking he said she can be pretend? I said yes malingering child. Asked what is this called? Functional visual loss. How to be sure? Examine her visual acuity from different distances, Fogging. what eye you will fog? the better eye. how do you do fogging? cover the better eye with +8 lens. (Notice this question was repeated in 1st trial glasgow 2015 )

**- Photo:**

Examiner gave me 12 leads ECG. I was shocked. I looked at Q wave & ST segment searching on myocardial infarction but I did not find I tried to count squares between RR intervals for Heart rate & arrhythmia. I can not talk for 2 minutes while I heard the examiner voice walking me up from my syncope asking is it normal ECG or not. I was saved I said it is normal. asked this Pt came to you for cataract surgery & had chest pain & treadmill test was normal what will you do? I will proceed surgery. Examiner but there is chest pain & pt give history of being recurrent. I did not comment. she asked what is that called I said stable angina she said right will you do surgery? I said yes he is stable is not he?. Again she objected what the risk for this pt? I said Myocardial infarction. She said right so you will do surgery I said after consultation of cardiologist & giving his medication I will do surgery she did not object. Asked this Pt when you proceed to do surgery he collapsed what will you do? I will give nitrate sublingual. She objected again nitrate in pt lost his

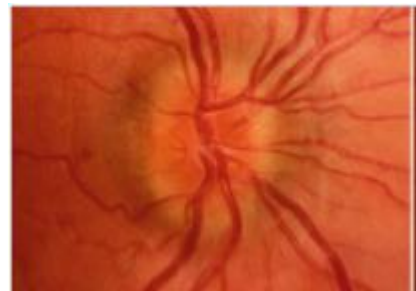



consciousness? I said I will do CPR. Asked How? I answered. Asked what is the rate of CPR 30:2. 30 chest compressions : 2 respirations

**-Photo:**

For 1st time I thought it is optic disc drusen. I started to describe. Elevated disc with dilated vessels. Examiner interrupted me asking this is a young lady & has this bilaterally? I answered papilledema from idiopathic increased cranial tension, Asked about management? history, symptoms & signs of ICT & treatment. but there is no hgs you see he? I said no asked about other diagnosis? DD of disc edema but I forget pseudo papilledema (e.g optic disc drusen. **(Other repeated question in my experience)**)



After this session I was frustrated. I thought that I will fail but it is The will of the God & I succeeded

**Posterior segment:**

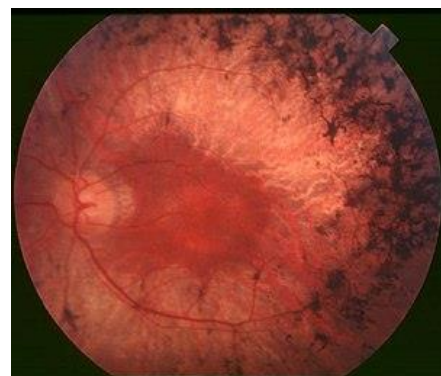**Question:**

causes of vitreous haze? proliferative diabetic retinopathy & mentioned other causes of retinal neovascularization, All causes of CNV, trauma, PVD, Retinal tear, Retinal detachment, eales disease, posterior uveities, macroaneurysm.

How to treat according to the cause. wait until haze resolved if not improved within 3 months then vitrectomy. Asked You will leave the Pt 3 months? If he does not want to wait we can do Vitrectomy without delay.

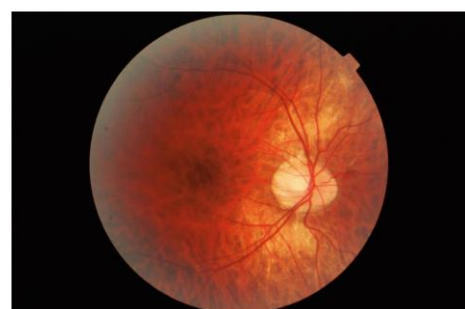**-Photo:**

Attenuated vessels, pale disc & bone spicules this is a case of Retinitis pigmentosa. Also the macula shows lesion I think it is atrophic maculopathy. Asked what is the effect of RP on macula? I said atrophic degeneration & epiretinal membrane. Asked what else? I said cataract, glaucoma, keratoconus, optic disc drusen **(he wanted cystoid macular edema the photo was RP with CME)** Asked what is systemic association with RP? Kjer's, abetalipoproteinemia, Refsum's, Usher & Bardet-Biedl disease.



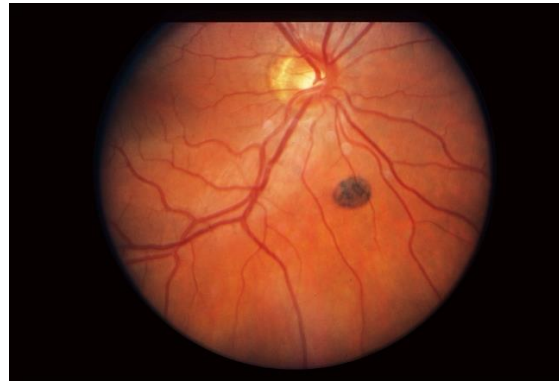**-Photo:**

Tigroid (fingerprint) fundus, pale disc, attenuated vessels. Examiner asked about All signs & complications of high myopia especially Foster-Fuchs dot, CNV.



**-Photo:**

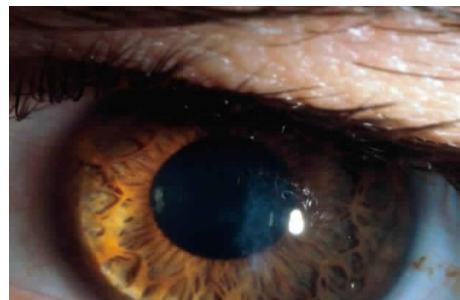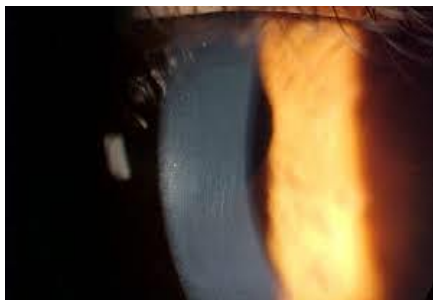pigmented well defined not raised flat lesion. How do you know it is not raised? blood vessel passing over the lesion is not kinked. what is this? choroidal nevus. Ask you think this lesion is benign? yes. why? away from optic disc not raised no subretinal fluid no orange pigmentation. What else it can be? Congenital Retinal Pigment Epith. Hypertrophy. Asked If CHRPE can be bilateral? yes there are 2 types solitary CHRPE & Atypical multiple CHRPE (polar bear track sign) this is associated with Familial Adenomatous Polyposis (FAP). Examiner said I don't know what is this FAP What is the syndrome? I think Gardner syndrome.



## **Clinical Exam:**

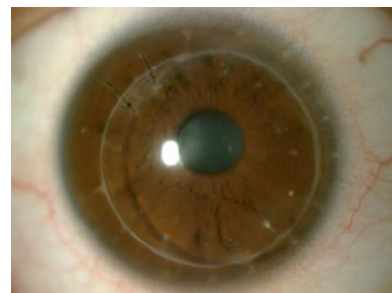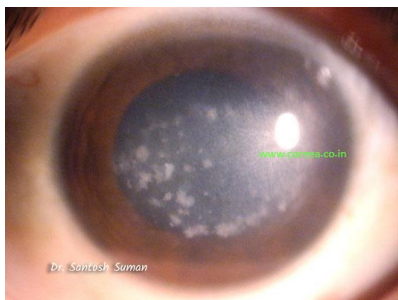### **Anterior segment:**

**1st case:** Examine Lt anterior segment



Lt eye cornea shows Vogt striae (keratoconus). other eye shows scar of hydrops. What do you think? a case of Keratoconus & Rt corneal scar from previous hydrops. what is your treatment? Lt eye mentioned from CL, corneal rings to keratoplasty. & Rt eye needs keratoplasty. What type of keratoplasty? Lt eye Lamellar keratoplasty (DALK) & Rt eye PKP as there is Descemet's scar from hydrops.

**2nd case:** Was young male. Examine Rt cornea

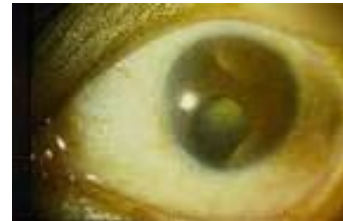

There are corneal stromal opacities & the intervening spaces are hazy. What is it? Can I see the other eye? OK. It shows keratoplasty. What type of keratoplasty? DALK. how

did you know? interface debris (which were very obvious). What is your diagnosis? Macular dystrophy with Lt keratoplasty as Macular dystrophy needs Keratoplasty early. (The right photo I put here is not good as in macular dystrophy there is corneal haze extending to limbus so corneal bed must be hazy)

**3rd case:** Examine anterior segment of that child:

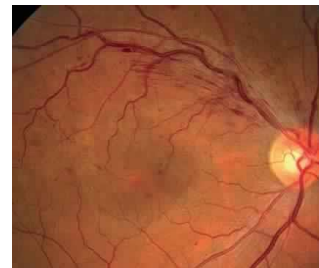
There was Nystagmus, Microcornea, Iris coloboma & cataract. What will you do? I think as there is nystagmus so the visual potential for this eye is poor so I counsel the Pt for only follow up. What is the cause of this nystagmus? may be the coloboma is extended to macula. Will you do cataract to him? No only conservative. OK you decided to do cataract what is the difficulty? Lens subluxation so capsular tension ring is needed. When you will put it? some surgeons prepher after removal of the nucleus & others put it from the start. 2nd difficulty is small eye so No IOL. You will not put IOL? According to white to white distance I will search for small diameter IOL & if very small eye I will not put IOL. You will leave him aphakic? Yes I will use Contact lens or specs. both Examiners was satisfied



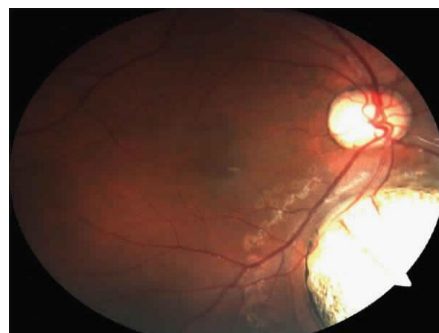
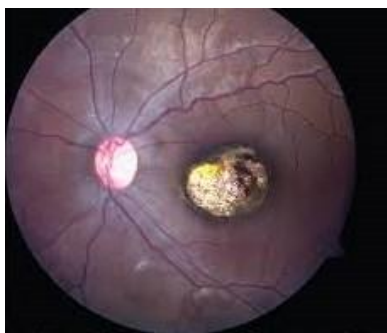## **Posterior segment:**

**1st case:**

Branch retinal vein occlusion with macular edema  
What is your management? FFA & OCT then Treatment is by grid laser photocoagulation or Anti VEGF injection.  
then follow up for neovessels formation & if happened I will do sector PRP



**2nd case:**



Use the indirect ophthalmoscope & examine this child Rt eye :  
there is macular scar also there is choroidal coloboma (I'm sorry I can not find one photo with both finding so I put 2 photos).

What do you think the cause of this scar? I want to examine other eye if bilateral.  
Examiner said ok other eye has coloboma but no macular scar. this scar may be toxoplasmosis or traumatic. What will you do to him? only follow up as the visual

potential of the other eye is good. What is the risk of this coloboma? retinal detachment. Examiner said so what to do? Retinal retinopexy

## **Oculoplasty :**

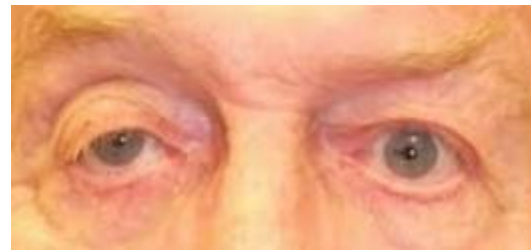### **1st case:**

Unilateral Rt axial exophthalmos. How did you know it is axial? by pen touch (hirschberg test). How you confirm proptosis? I examined from up & both sides. I want to do measurements Examiner said ok go. There was a ruler beside the Pt I used it to measure. After that a normal discussion about TED ocular & systemic fissures with application on Pt

### **2nd case:**

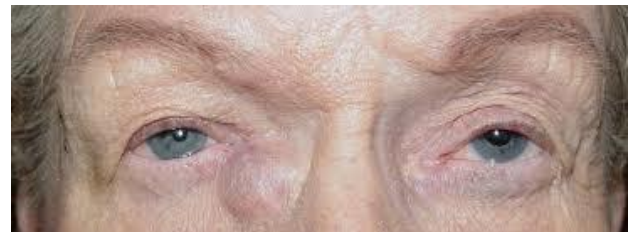Examine this old man:

There is Rt ptosis . pupils are equal & reactive. prominent lid sulcus. I used my ruler & started to measure lid crease (high lid crease), MRD & levator function (which was good). what is your diagnosis? aponeurotic ptosis. What is your management ? Aponeurotic repair.



### **3rd case:**

Mass on the inner canthus under medial palpebral ligament, non tender & firm in consistency. What is your diagnosis? Chronic dacryocystitis. Examiner asked anything else? I stopped taking for seconds then I noticed faint scar in both sides do I said there is scar of previous surgery in both sides. Asked what surgery? dacryocystorhinostomy.



## **Neuro & ocular motility:**

### **1st case:**

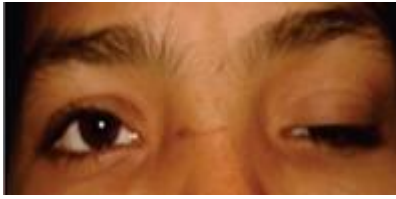Pupil sparing 3rd nerve palsy with discussion about causes & management

### **2nd case:**

Young male with nystagmus. Examiner asked me to examine him. I said horizontal conjugate pendular nystagmus of medium amplitude & rate. Can I do ocular motility? Examiner said go. nystagmus it was dampened by convergence & increased by fixation. Also it was dampened in Rt gaze (null point). What is your diagnosis? congenital nystagmus. How do you confirm this ? by history of being since birth & I will ask about oscillopsia. If no oscillopsia so it is not acquired. What else you will do to confirm it is congenital? I don't know (he wanted to do cerebellar signs as disdiadokokinesia, finger to finger & finger to nose tests, walking gate)



3rd case:



Pt Rt eye was normal. Lt eye shows complete ptosis (totally closed). Levator function is very poor = 0. I elevated this ptotic lid to find hypotropic eye in 1ry position.

I asked the examiner to do EOM movement & he agreed. All gazes were normal except all elevation gazes were limited (elevation & elevation in adduction elevation with abduction).

Examiner Asked Ok what is your diagnosis? I said I can give differential Diagnosis. Blow out Fracture Examiner said No what else? I said monocular elevator palsy. Examiner did not object & asked what will you do next? I said Forced duction test (FDT) to exclude Blow out fracture. Examiner Asked In Mono ocular elevation palsy what do you expect from FDT? may be +ve or -ve according to the cause. He did not object & asked what is your treatment. I said IR recession for hypotropia & Frontalis suspension for ptosis as Levator function is poor. Examiner was happy (in my DD I forget partial 3rd nerve palsy)

Thanks so much  
I hope it was helpful to you

Dr. Kareem Elsheikh FRCS(Glasgow)  
Contact me: Dr.kareemelsheikh@gmail.com